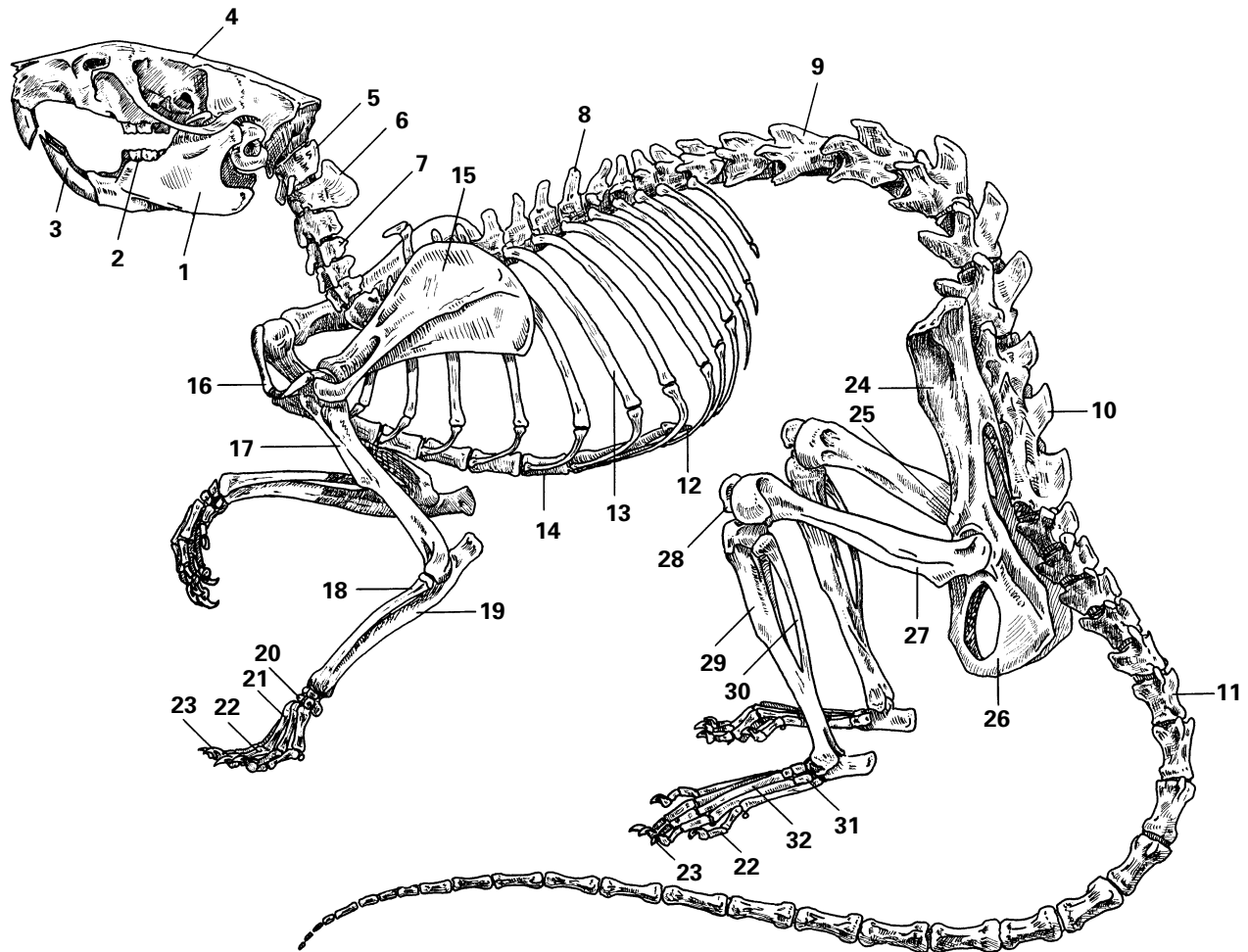


# Rat Skeleton



- |                             |                 |
|-----------------------------|-----------------|
| 1. Mandible                 | 17. Humerus     |
| 2. Molar                    | 18. Radius      |
| 3. Incisor                  | 19. Ulna        |
| 4. Skull                    | 20. Carpals     |
| 5. Atlas                    | 21. Metacarpals |
| 6. Axis                     | 22. Phalanges   |
| 7. Cervical vertebra (7)    | 23. Claw        |
| 8. Thoracic vertebra (13)   | 24. Ilium       |
| 9. Lumbar vertebra (6)      | 25. Pubis       |
| 10. Sacrum (3)              | 26. Ischium     |
| 11. Caudal vertebra (28–30) | 27. Femur       |
| 12. Xiphoid process         | 28. Patella     |
| 13. Rib (13)                | 29. Tibia       |
| 14. Sternum                 | 30. Fibula      |
| 15. Scapula                 | 31. Tarsus      |
| 16. Clavicle                | 32. Metatarsus  |